

Homoeopathic Management of Renal Calculi with Mild Prostatic Enlargement and Genital Herpes: A Clinical Case Report

Dr Khyati Lakhani¹, Prof. Dr. A. N. Mathur^{2*}, Dr Ankur Desai³

Corresponding author

Dr Khyati Lakhani¹

PhD Scholar from Homoeopathy University, Jaipur, HOD & Professor, Department of organon of Medicine & Homoeopathic Philosophy- PG, Parul Institute of Homoeopathy and Research, Parul University, Vadodara, Gujarat

Email ID: drkhyatilakhani511@yahoo.com

1. PhD Scholar from Homoeopathy University, Jaipur, HOD & Professor, Department of Organon of Medicine & Homoeopathic Philosophy - PG, Parul Institute of Homoeopathy and Research, Parul University, Vadodara, Gujarat
2. President in Homoeopathy University, Jaipur
3. Principal, HOD & Professor in Department of Pathology & Microbiology in Parul Institute of Homoeopathy and Research, Parul University, Vadodara, Gujarat

DOI: 10.63001/tbs.2025.v20.i04.pp850-855

Received on:

22-09-2025

Accepted on:

12-11-2025

Published on:

04-12-2025

Abstract

A 35-year-old male patient presented with renal calculi as the chief complaint since July 2023. The case started as one sided disease having few symptoms. Ultrasonography revealed mild prostatomegaly with it. Also, history of genital herpes was revealed during case taking. The patient has taken allopathic treatment with only temporary relief. So the relevance of renal calculi with mild prostatic enlargement and genital herpes in a single case lies in their clinical overlap, diagnostic complexity and homoeopathic management challenges. The case was managed by Cantharis, Berberis vulgaris and Merc.Sol and Lifestyle modifications including dietary restrictions and hydration guidance. Over a period of six weeks, the patient showed marked symptomatic improvement. Follow-up ultrasonography after fourteen weeks showed no evidence of the calculus and even normal sized prostate. There are also no symptoms of herpes. It demonstrates scope of Homoeopathy in treating multi- system, chronic case and the need for further clinical research in similar multi-morbid presentations.

Introduction

- Renal calculi, benign prostatic hyperplasia and genital herpes are common urogenital conditions, particularly affecting middle – aged and older males. Renal calculi are

the most common condition in day-to-day practice¹ and cause of significant morbidity in our society. It is estimated that approximately 12% of the population will have a renal stone at some point in

their lives. The incidence of urinary calculi increases with age, attaining a maximum in the 30-45 years. After the age of 60 years, the prevalence decreases.

2

- BPH may predispose individuals to urinary tract infections and promote calculus formation due to urine stasis.³

- Genital Herpes affects over 400 million people worldwide and is often underreported due to social stigma.⁴

- Homoeopathy is gentle system of healing & perfectly safe to use in cases of renal stone .By following the guideline of master Hahnemann in case taking we can make a prescriptive totality and can prescribe proper homoeopathic treatment. There are many good remedies for renal calculi like Berberis Vulgaris, Calcarea Carb, Cantharis, Hydrangea Arborescens, Lycopodium Clavatum, Pareira B, Sarsaparilla, Terebinthina, Ocimum Can, Uva Ursi etc.⁵ Homoeopathic medicines can break down and dissolve renal stones or help them pass out and also help in relieving the agonising pain. It is also cost-effective

and minimise its recurrence. They reduce dependence over other and also surgery.⁶

Materials & Methodology

- Date :26/10/24
- Name :MHP
- Age : 35 years
- Gender :Male
- Education: 12th std
- Religion: Hindu
- Occupation :Shop-keeper
- Address: Chhota-Udaipur
- Renal calculi since July 2023.

Clinical findings

- Renal calculi since July 2023. (4mm calculus at mid calyx of left kidney.)
- Burning⁺⁺⁺ urination <evening⁺⁺⁺, waking on since 2023. Had taken allopathic medicine with no satisfactory improvement.
- Urine :pale yellow,3-4 times morning/night
- Mild prostatomegaly without significant post void urine.
- If doesn't drink water ,no desire to urination ,doesn't have burning
- Dull aching pain in left lumber region<jarring
- Desires : spicy , sour
- Doesn't like sweets, garlic
- Ambithermal

- Dry spots of herpes on genitals.
- Eruptions of herpes < by silk materials
- Grinding of teeth at night before 2-3 years

Mentals:

- Tension of herpes on genitals
- Angry if there is garlic in food.
- Irritable +++ before eruptions of herpes

Past History

- Herpes on genitals since 2008-Had taken allopathic medicine
- High Cholesterol since last 2 years –

Repertorial Totality (Synthesis)

taking allopathic medicine

- Piles –bleeding before one year –operated.

Family History

- Mother –Thyroid ,knee replacement , Herpes simplex
- Father –Hypertension, Prostate , Gall bladder stone –cholecystectomy
- Uncle –Herpes simplex

Miasmatic Evaluation

Syco -Syphilitic

Diagnostic Assessment

1. Clinical Symptoms
2. USG –KUB

Remedy	Rubrics Covered
Lycopodium	4/4
Cantharis	3/4
Sarsaparilla	3/4
Sulphur	2/4
Sepia	2/4
Natrum Mur	2/4
Nux vomica	2/4
Conium	1/4

Therapeutic Intervention

Date :26/10/24

R_x

Cantharis 30 tds for 15 days

Follow up & Outcome

Date	Change in symptomatology	Prescription
11/11/24	60-70% relief in first week .But after that again the same trouble	R _x Cantharis 200 TDS for 1 week.
19/11/24	S.Q. in burning Urination. Occ. Dull aching pain in left lumbar region<jarring	R _x Berberis Vulgaris 30 TDS for 1 month
20/12/24	Occ. Pain in left lumbar region. No burning in urination	R _x Berberis Vulgaris 30 TDS for 1 month
22/1/25	Occ. Pain in left lumbar region. In between 2-3 times severe burning during Urination	R _x Berberis Vulgaris 30 TDS for 1 month
18/2/25	No pain 2-3 times severe burning during urination H/O Herpes in genitals-dry eruptions	R _x Merc Sol 200 –one dose Berberis vulgaris 30 TDS for 1 month
19/3/25	No pain No burning during urination Now no spots of herpes on genitals	R _x Merc Sol 200 –one dose Berberis vulgaris 30 TDS for 15 days Patient was advised for USG-KUB
31/3/25	No pain No burning during urination No spots of herpes on genitals USG-KUB reveled no calculus, even prostate is normal in size, shape measures 25cc volume.	R _x Merc Sol 200 –one dose Sac lac 200 TDS for 15 days

Outcome:

Over a period of six weeks, the patient showed marked symptomatic improvement. Follow-up ultrasonography after fourteen weeks showed no evidence of the calculus and even normal sized prostate. There are also no symptoms of herpes.

USG –KUB REPORT

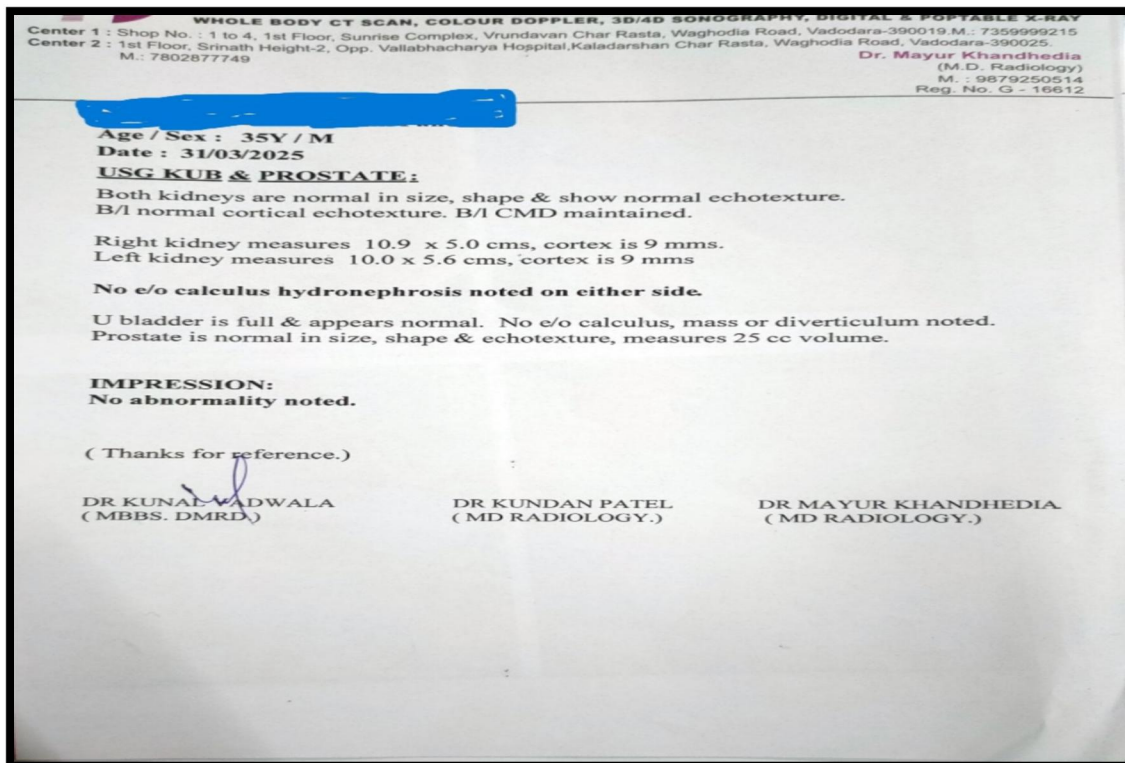
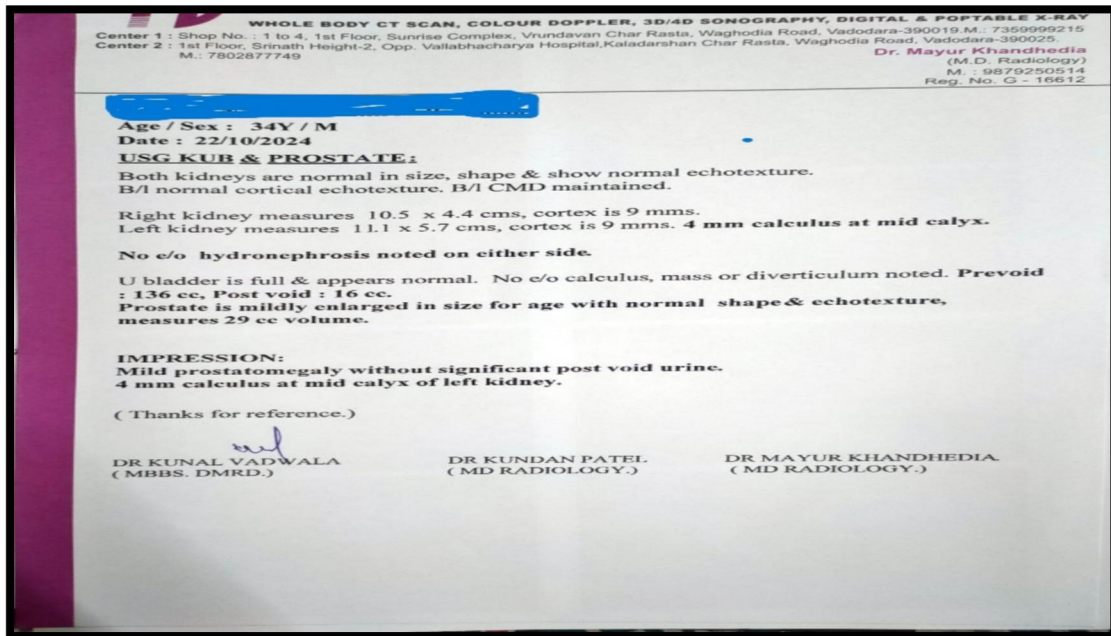


Figure. No. 2. USG-KUB after Treatment part

Discussion

This evidence-based case underscores the efficacy of Homoeopathic management in case of renal calculi with mild prostatic enlargement and genital herpes, restoring the highest ideal of cure. Homoeopathy plays a significant role in symptom relief and stone expulsion, highlighting its opportunity in renal calculi management. It gives us scope for larger clinical studies.

Acknowledgment

Authors would like to thanks Homoeopathy University and Parul University for the Research work

Reference

1. Renal calculi and its homoeopathic management by using rare mother tincture,

Dr. Priya Patil and Dr. Ch. Premalatha, IJHS 2021; 5(3): 256-259

2. A study to ascertain the effect of berberis vulgaris, hydrangea, cantharis, lycopodium clavatum and staphysagria in renal calculi, International Journal of Homoeopathic Sciences 2021; 5(1): 25-28

3. Relationship between urinary stasis and stone formation, Yachia D. J Urol , 1990

4. Herpes Simplex virus, WHO, 2020

5. Pocket Manual of Homoeopathic Materia Medica & Repertory, Dr. William Boericke

6. A study to ascertain the effect of berberis vulgaris, hydrangea, cantharis, lycopodium clavatum and staphysagria in renal calculi, International Journal of Homoeopathic Sciences 2021; 5(1): 25-28